

Artículos sobre técnicas

Immunoperoxidase staining with *Ior Cama-1* monoclonal antibody in the detection of breast cancer lymph node metastases

B.R. TORMO,¹ M. ALFONSO,¹ E. RENGIFO,¹ S. FRANCO² AND A. CHONG³

¹ Hybridoma and Quality Control Lab. Center of Molecular Immunology (CIMAB), 29 y E Vedado, Ciudad de La Habana, Cuba.

² Pathology Department. National Institute of Oncology and Radiobiology. 29 y E, Vedado, Ciudad de La Habana, Cuba

³ Pathology Department. "Hermanos Ameijeiras" Hospital. San Lázaro 701, Ciudad de La Habana, Cuba

Recibido en septiembre de 1991

Aprobado en julio de 1992

SUMMARY

The presence of axillary metastasis in carcinoma of the breast is of major prognostic significance.

Experienced trained pathologists may miss small tumor deposits in routine histological screening of H&E stained sections. In consequence the avidin-biotin-peroxidase complex immunohistochemical method was used to evaluate if the *ior cama1* monoclonal antibody (Mab), with a wide reactivity to normal and tumor tissues of non lymphoid histology, was specific and sensitive in detecting breast cancer cells in lymph node metastases.

The results show that immunoperoxidase staining with *ior cama1* clearly highlights small metastatic deposits.

RESUMEN

La presencia de ganglios axilares metastásicos es de gran valor pronóstico en el cáncer mamario.

La presencia de pequeños focos metastásicos puede escaparse al ojo del patólogo más experimentado durante el estudio histológico de rutina de las muestras teñidas con H&E. Es por ello que se empleó el método inmunohistoquímico complejo de avidina-biotina peroxidasa para evaluar si el anticuerpo monoclonal (AcM) *ior cama1*, de una amplia reactividad en tejidos normales y tumorales de

origen no linfóide, presenta una alta especificidad y sensibilidad para detectar células de tumores de mama en micrometástasis ganglionares.

Los resultados demuestran que la tinción por inmunoperoxidasa con el AcM *ior cama1* destaca claramente los pequeños depósitos metastásicos.

INTRODUCTION

Breast cancer is the first cause of death from malignant disease in women in our country.

Established factors of prognostic significance in breast carcinoma are the clinical stage of the disease which encompasses the tumor size, axillary lymph node involvement, and distant tumor estrogen receptor content^{1,2}.

It is generally accepted that clinical outcome varies with the number of lymph nodes involved by tumor^{2,3}. Patients with negative nodes have 65% five year cure rate, patients with positive nodes have cure rates ranging from 10-48%, depending on the

number of positive nodes². Attiyeh, *et al.*⁴ found that patients with 1-3 nodes containing metastases exhibited significantly worse survival rates than those without nodal metastases, but better survival rates than those with 4 or more involved nodes.

This lymph node categorization is useful in determining patients likely to have early recurrences and be considered when choosing patients for aggressive adjuvant treatment³.

Moreover, as many as 20% of those patients deemed to be axillary node-negative on routine histopathological examination, and therefore with an anticipated favourable outcome relapse within 5 years³. This observation highlights the possible role of occult metastatic disease.

The use of immunohistochemical techniques to detect tumor micrometastases has been previously reported⁵⁻⁸. These have predominantly relied on home-made or commercial cytokeratin or epithelial membrane antigen antibodies. We report the use of ior-CAMA-1, a new monoclonal antibody (Mab) with a wide spectrum reactivity to normal and tumor tissues of non-lymphoid histology (manuscript in preparation) that nonetheless, demonstrates a high specificity and sensitivity in detecting breast cancer cells in lymph node metastases.

MATERIALS AND METHODS

Generation of the ior cama1 monoclonal antibody

Splenocytes from Balb/c mice immunized with membrane extracts of breast cancer cell line MCF7 were fused with the P3/X63-Ag8-6.5.3 murine myeloma line as previously described (Fernández *et al.*, 1986). Hybridoma supernatants were tested by Ultramicroelisa (SUMA) for reactivity to ovary, lung, colon and breast tumor and cell line membrane extracts as well as ascitis from breast cancer patients, and several

clones selected. Analysis of radiolabelled membrane immunoprecipitates in SDS-PAGE showed that the ior cama1 monoclonal antibody precipitated high molecular proteins in two breast cancer cell lines: 236 kDa in MCF-7, and 165 kDa in MDA cell line (Alfonso *et al.*, 1992).

The MAB used in the work reported in this article was purified from ascitis by Protein A-sepharose chromatography.

Specimens

Tissue blocks of known axillary metastases from 5 cases of breast cancer were retrieved from the files of the National Institute of Oncology and Radiobiology and the Hermanos Ameijeiras Hospital. Assessment of micrometastases was based on the H&E sections by qualified pathologists. All nodes had been fixed in 10% buffered formalin solution, dehydrated, cleared and paraffin-embedded according to routine procedures.

Immunoperoxidase Staining

An avidin-biotin-peroxidase complex method was performed as previously described¹⁰. Briefly, sections were deparaffinized, endogenous peroxidase was blocked, and the sections were successively incubated with ior-CAMA-1 Mab for 1 hour at room temperature (r.t.), biotinylated secondary antibody (DAKOPATTS) for 30 min. at r.t., followed by avidin-biotin-peroxidase complex reagent (DAKOPATTS) for 30 min at r.t.. The peroxidase reaction was developed with a diaminobenzidine solution. Slides were counterstained with Mayer's hematoxyline. Negative control staining was obtained by substituting the primary antibody with TRIS buffer saline (TBS).

Data Analysis

Appropriate automatic programs for statistical tests were performed (Microsta, Epistat).

RESULTS

Lymph nodes removed from five female patients with breast cancer and known axillary micrometastases demonstrated ior-CAMA-1 positive metastatic tumor cells (figs. 1 and 2), distinct from the surrounding negative lymphoid cells.

The immunoperoxidase-stained tumor cells, organized in clusters (fig. 1) or as single cells in files (fig. 2), were readily detected with an X4 objective (X10 eyepiece). The ior-CAMA-1 Mab showed a distinct

cytoplasmic staining with no background as previously observed in breast cancer tumors during the immunostaining pattern study of this Mab (manuscript in preparation).

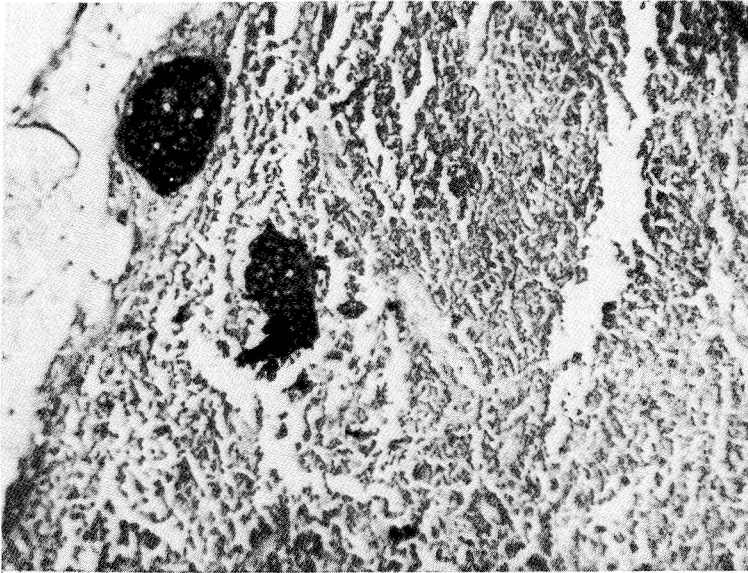


FIG. 1. Infiltrating duct carcinoma axillary lymph node metastases. Clusters and single cells are strongly stained with ior-CAMA1 (X125).

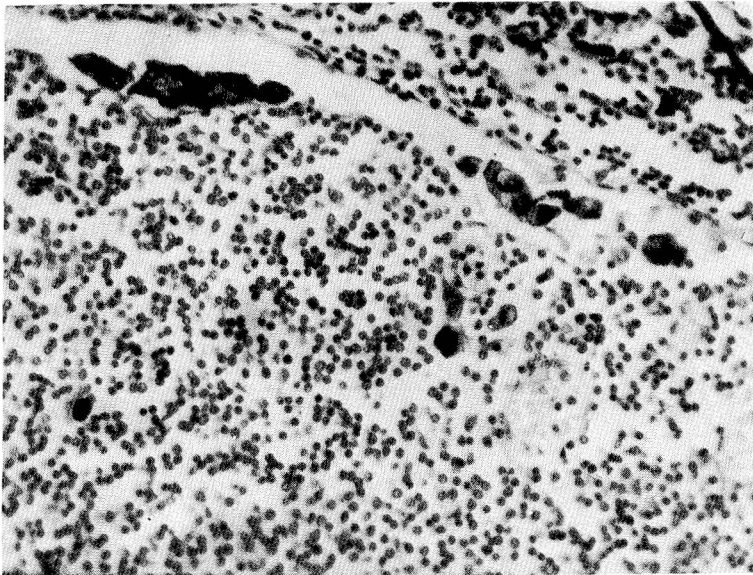


FIG. 2. Infiltrating duct carcinoma axillary lymph node metastases. Single cell, isolated or in files are clearly identifies (X250).

DISCUSSION

We illustrate that the immunohistochemical detection of ior-CAMA-1 positive axillary metastases, is a sensitive method. This Mab shows a strong reactivity with breast cancer cells and is non reactive with lymphoid cells.

According to W. Raymond and A. Long⁸ serial sectioning of axillary nodes has been shown to increase the detection of metastatic deposits. However, this method is labour-intensive and time-consuming. Routine histological screening is usually performed at low magnification (X4 or X10 objective) at this power small tumor deposits can be difficult to differentiate from other elements of the lymph node. Screening at higher magnification is not a more accurate technique and may not allow a distinction between tumor and non-tumor cells. In contrast we showed that immunoperoxidase staining with ior-CAMA-1 Mab clearly highlights metastatic deposits.

Experienced trained pathologists may miss small metastatic tumor foci in axillary lymph nodes. Because of the possible prognostic implications of missing such deposits we are currently performing an immunohistochemical study with ior-CAMA-1 Mab on a series of over 100 patients (T1, T2, N0 according to UICC classification) classified as T1 or T2N- after H&E standard sections to validate its role in detecting occult metastatic disease.

The ior-CAMA-1 Mab is being used with excellent results in routine immunohistochemical stainings in lymph node metastases where tumor identification is a problem.

REFERENCES

1. DAWSON, P.J.; D.J. FERGUSON and T. CARRISON (1982). The pathologic findings of breast cancer in patients surviving 25 years after radical mastectomy. *Cancer* **50**: 2131-2138.
2. WEIGAND, R.A.; W.M. ISENBERG, J. RUSO *et al.* (1982). Blood vessel invasion and axillary lymph node involvement as prognostic indication for human breast cancer. *Cancer* **50**: 962-9.
3. FISHER, E.; S. SWAMIDOSS; C.H. LEE; H. ROCKETTE; C. REDMOND and B. FISHER (1978). Detection and significance of occult axillary node metastases in patients with invasive breast cancer. *Cancer* **42**: 2025-31.
4. ATTIYEH, F.F.; M. JENSEN; A.G. HUVOS and A. FRACCHIA (1977). Axillary micrometastases and macrometastases in carcinoma of the breast. *Surg. Gynecol. Obstet.* **144**: 839-42.
5. WELLS, C.A.; A. HERYET; J. BROCHIER *et al.* (1984). The immunocytochemical of axillary micrometastases in breast cancer. *Br. J. Cancer* **50**: 193-7.
6. BUSSOLATI, G.; P. GUGLIOTTA; I. MORRA *et al.* (1986). The immunohistochemical detection of lymph node metastases from infiltrating lobular carcinoma of the breast. *Br. J. Cancer* **54**: 631-6.
7. SEDMACK, D.D.; T.A. MEINEKE and D.S. KNECHTGES (1989). Detection of metastatic breast carcinoma with monoclonal antibody to cytokeratins. *Arch. Pathol. Lab. Med.* **113**: 786-789.
8. WENDY, A.R. and A. S. Y. LEONG (1989). Immunoperoxidase staining in the detection of lymph node metastases in stage I breast cancer. *Pathology* **21**: 11-15.
9. FERNANDEZ, A.; C. HERMIDA; J.V. GAVILONDO and I. ALVAREZ (1986). Utilización de líneas celulares de cáncer mamario humano en la obtención de anticuerpos monoclonales que reconocen tejido tumoral. *Interferon y Biotecnología* **3**: 125-210.
10. HSU, S.M. and L. RAINE (1981). *J. Histochem. Cytochem.* **29**: 1349-53.